

Toxicity of Flunixin Meglumine in Broiler Chickens

*[#]Muhammad Ramzan, *Muhammad Ashraf, **Khawaja Tahir Mahmood

**Department Of Pharmacology and Toxicology, University of Veterinary and Animal Sciences, Lahore,*

***Sr .Pharmacist, DTL, Punjab, Lahore Pakistan.*

[#]drramzan2004@yahoo.com

Abstract

This study was designed to evaluate the toxicity of flunixin meglumine, a nonsteroidal anti-inflammatory drug which might serve as an alternate of diclofenac that has been shown to cause toxicity in vultures. Twenty five broiler chickens of five weeks of age were randomly divided into five equal groups and treated with flunixin meglumine at the dosage rate of 0, 1.25, 2.5, 5 and 10 mg/kg body weight for four consecutive days, intramuscularly. Clinical signs, mortality, gross and microscopic lesions in visceral organs were recorded and serum concentrations of uric acid, creatinine, AST, ALT and ALP were measured. The affected birds exhibited the signs of toxicity as anorexia, depression, lethargy and coma. Mortality rates in 2.5, 5 and 10 mg/kg groups were 20, 40 and 60%, respectively. Gross lesions included visceral gout characterized by multifocal to locally extensive urate precipitates on almost all the visceral organs, skeletal muscles and sub cutis. Microscopic lesions showed multifocal urate tophi frequently surrounded by inflammatory cells. A strong correlation in the toxicity of the drug and elevation of the serum uric acid and creatinine concentrations was observed in the affected birds. We propose that flunixin meglumine causes similar toxicity in birds as diclofenac does.

Key words:

Flunixin meglumine, Nonsteroidal anti-inflammatory drugs, Drug toxicity, Visceral gout, Renal damage, Broiler chickens

INTRODUCTION

Recently a sharp decline in vulture population has been observed in Southeast Asia (1, 2, 3). International Union of Conservation of Nature (IUCN) has estimated that at least three vulture species i.e. *Gyps bengalensis*, *Gyps indicus* and *Gyps tenuirostris* have become critically endangered (4). Many causes for decline in vulture population have been postulated including food shortage, habitat loss, human persecution, environmental contaminants and infectious agent (5). However, recent studies found that the residues of diclofenac, a non-steroidal anti-inflammatory drug (NSAID) may be responsible for the vulture mortalities (6). Diclofenac is an antipyretic, analgesic and anti-inflammatory drug and is commonly used in the region to treat sick domestic animals (7). Vultures consume diclofenac residues in the meat of dead animals treated with this drug shortly before death (6, 8, 9). Vultures play a significant role in maintaining the ecological balance so their presence in the ecosystem seems important. Therefore an alternate NSAID is needed to replace diclofenac in veterinary medicine which may, at least be equally efficacious but safer for the scavenging birds.

Flunixin meglumine (FM) is another NSAID and is being used in veterinary practice around the world. Flunixin is used alone or in combination with antimicrobial agents to treat a variety of diseases in domestic animals like, lameness (10, 11), colic (12), endotoxemia (13), mastitis (14), metritis (15) and respiratory diseases (16). This suggests that flunixin may be a potential alternative of diclofenac for treatment of sick domestic animals.

Since it is hard to get vultures for research, in a preliminary study, we searched other bird species that exhibited diclofenac toxicity similar to that observed in vultures. The preliminary study showed that, similar to the observations in vultures, broiler chickens were also sensitive to diclofenac and suffered from toxicity (unpublished data). Moreover, other studies have also used chickens as a model to study NSAID's pharmacological and toxicological effects (17, 18, 19).

Therefore, the aim of this study was to evaluate whether flunixin can be used in animals as an alternative to diclofenac, without serious toxicity in vultures.

MATERIALS AND METHODS

Birds:

Twenty five, 1-day old broiler chicks were obtained from a local hatchery. The chicks were brooded on fresh litter. The room temperature was maintained at 33°C during first week and then reduced by 3° per week subsequently till 24°C and that temperature was maintained for rest of the period. Birds were vaccinated against ND, IBD and IB as per schedule and provided with clean water and commercial broiler starter ration *ad libitum*. Light remained on for 24 hours a day.

Drug:

A 50 mg/ml solution of flunixin meglumine (Loxin, Selmore Pharmaceutical, Pakistan) was used.

Experimental Design:

The birds were randomly divided into five groups A, B, C, D and E containing five birds in each group.

Birds in group A (control) were injected with physiological normal saline solution (PNS) at the dosage rate of 0.2ml/kg body weight intramuscularly. Birds in groups B, C, D and E were treated with flunixin meglumine at the dosage rate of 1.25, 2.5, 5 and 10 mg/kg body weight respectively, intramuscularly every 24 hours. Right and left pectoral muscles were used for the injection alternatively, for four consecutive days. The volume of injection was made to 0.2ml/kg for each bird by diluting the drug in distilled water.

Clinical signs and mortality rates:

Experimental birds were observed for any abnormality in feed and water intake and demeanor. The clinical sign exhibited by these birds were recorded. The mortality in each group was also noted.

Blood sampling:

Blood (1.5 ml) was drawn from brachial vein either before or at 24, 48, 72 and 96 hours after the start of dosing. The blood was immediately transferred in glass test tubes. Serum was separated from these samples and stored at -20°C for further analysis.

Biochemical analysis:

Serum samples were analyzed for Aspartate Transaminase (AST), Alanine Transaminase (ALT), Alkaline Phosphatase (ALP), Uric Acid (UA) and Creatinine (CREA) using commercially available diagnostic kits (RandoxLaboritories, UK) by Spectrophotometer (UV-1650PC, Shimadzu Corporation, Japan).

Urate confirmation:

White chalky material collected from pericardial sac was analyzed through Murexide reaction (20) for the confirmation of urates. Development of mauve color was considered positive for the presence of urates. Urine urate deposits and egg albumen were used as positive and negative controls, respectively.

Gross and histopathologic examination:

The birds that died during the experimental period were necropsied immediately. The surviving birds in treatment groups and those in control group were sacrificed and examined for gross pathologic lesions at the end of experiment. These lesions were recorded for each bird. Tissue samples of kidney, liver, heart, spleen and skeletal muscle were collected from each bird and fixed in 10% neutral-buffered formalin. These samples were processed through paraffin embedding technique to prepare the sections of 3µm thickness. These sections then, stained with haematoxylin and eosin stain using standard procedures. The stained slides were examined for histopathologic changes.

Animal care and handling:

The experimental birds were handled according to the guidelines established by University of Veterinary and Animal Sciences, Lahore, Pakistan.

Statistical Analysis:

All statistical analyses were performed using PRISM 5 (GraphPad Software, San Diego, CA, USA). Mean and Standard Deviation were calculated using ANOVA and the significance between two means was determined using Student's t-test. A $p < 0.05$ was taken as an indication of significance between two means.

RESULTS

Mortality rates:

No mortality was observed in groups A (control) and B (flunixin meglumine, 1.25 mg/kg b w). One bird was died in group C (flunixin meglumine, 2.5 mg/kg) at 56 hours after first dosing. One bird in group D (flunixin meglumine, 5 mg/kg) was died at 59 hours while the 2nd one died at 75 hours after the start of experiment. The three birds in group E (flunixin meglumine, 10 mg/kg) were died at 51, 63 and 69hours after first exposure (Fig. 1). The mortality in groups C, D and E was recorded as 20%, 40% and 60%, respectively.

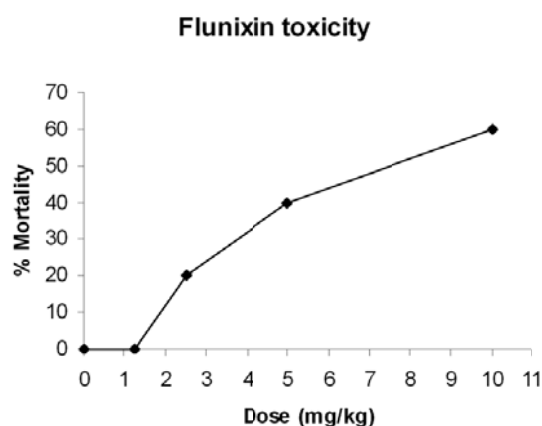


Figure-1: Mortality in broiler chickens exposed to various doses of flunixin meglumine

Clinical Signs:

The birds that died before completion of the experiment showed clinical signs approximately 24 hours post-exposure. They exhibited the signs of depression, anorexia, lethargy and reluctance to move. They showed stiff gait and felt difficulty in walking and standing. They perched aside with ruffled feathers and eyes closed. Affected birds remained sitting on the ground with their heads down. They could hardly move when forced to and had tendency to sit again soon. Respiration of

affected birds was deep and rapid. Prior to death, the affected birds became comatose. Deaths occurred mainly between 48 and 72 hours after initiation of treatment. The survived birds in groups C, D and E remained apparently normal. The birds in group A appeared clinically healthy and did not manifest the signs of toxicity described above.

Gross Lesions:

Postmortem examination conducted on 6 chickens that died (1 in group C, 2 in group D, 3 in group E) revealed almost similar lesions.

The major gross lesion was mild to severe and widespread deposition of a mixture of white chalky material (uric acid crystals), white debris (uric acid), and varied amount of fibrinous exudate (Fig. 2).

The precipitation of urates varied from multifocal to locally extensive areas present in the subcutaneous tissues (abdominal and cervical region), pectoral muscles, thigh muscles, air sacs, thoracic wall serosal surface, pericardium, epicardium, sternum, abdominal fat, abdominal wall serosal surface, serosal surface of liver, spleen, proventriculus, ventriculus, entire intestinal tract, kidneys, and articular surface within mandiblar, hip and hock joints. Small uroliths were found in segments of urethra and urethral openings of the cloaca.

The liver was friable and kidneys were pale-tan and swollen. Varied amounts of white debris and fibrin were scattered on most of the visceral serosa.

Other four birds (2 birds each in groups D and E) showed mild to moderate swelling and pale discoloration of kidneys when examined after slaughtering at the end of experiment. Necrosis of pectoral muscles at the site of injection was observed in the birds treated with flunixin meglumine at the dose rate of 10 mg/kg b.w.

No gross lesions were found in the birds of groups A and B at the time of necropsy.

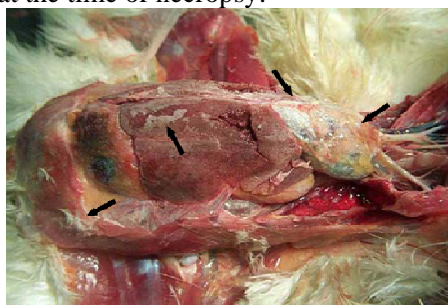


Figure-2: Broiler chicken (group D, 5-week-old) treated with flunixin meglumine at the dose rate of 5 mg/kg b.w. showing visceral gout with varied amounts of urates (white/gray chalky material) present on the serous membranes: pericardium, liver, gizzard, peritoneum (arrows).

Histopathological Lesions

Basically, all the dead birds in all treatment groups had similar microscopic changes.

Kidney: There are multifocal, variably-sized (up to 200 µm in diameter), colorless to basophilic radiating, sharp, acicular, crystalline deposits (urate tophi) that are expanding and replacing renal tubules and extending into the adjacent cortical interstitium, and frequently surrounded by low to moderate numbers of macrophages a fewer multinucleated giant cells, occasional heterophils, and a few scattered cellular and karyorrhectic debris. Multifocally, tubules are mildly dilated (ectatic), with attenuated epithelium, and usually contain a mixture of amorphous eosinophilic material, sloughed epithelial cells and cellular debris (Fig. 3).

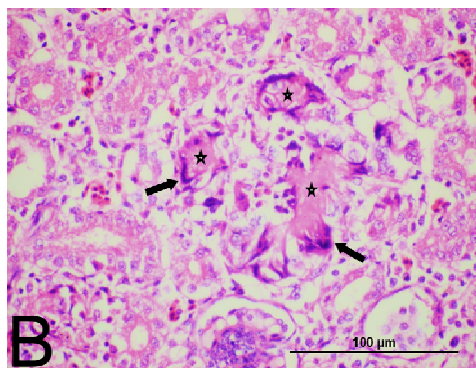


Figure-3: Histomicrograph of kidney tissues of a broiler chicken treated with flunixin meglumine 10 mg/kg (group E). Several urate tophi (star) have stimulated an early multinucleated giant cell response at their periphery (arrow). Note acicular urate tophi disrupting the architecture of the proximal convoluted tubules. H&E, 400x. Bar = 100 µm.

Liver: There are multifocal, random, variably-sized tophi surrounded by inflammatory cells as previously described (Fig. 4).

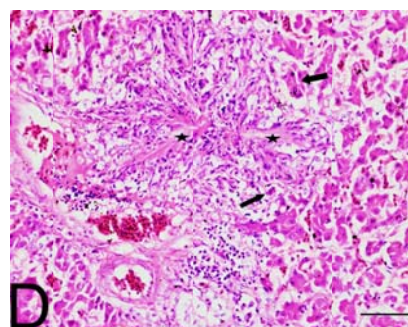


Figure-4: Histomicrograph of liver of a broiler chicken treated with flunixin meglumine 5 mg/kg (group D), showing radiating urate crystals (arrows). Urates have been dissolved out of the tissue during the tissue processing, however, the crystalline pattern of their deposition is visible, surrounded by heterophilic inflammation, necrotic debris, and a few multinucleated giant cells (star). H&E, 600x, Bar = 100 µm.

Heart: Multifocal, random, urate topi as previously described are scattered throughout the cardiac muscle (Fig. 5).

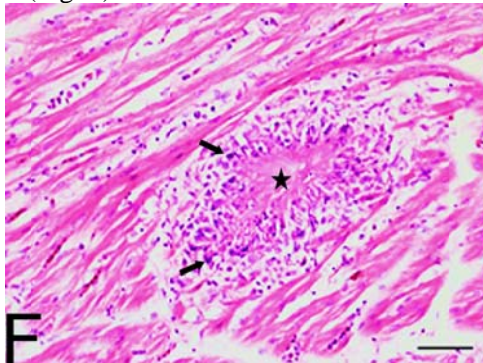


Figure-5: Histomicrograph of cardiac muscle of a broiler chicken treated with flunixin meglumine 10 mg/kg (group E). Tophus formation is shown in a section (star). Lesions consist of radiating urate crystals surrounded by macrophagic and heterophilic inflammation and occasional multinucleated giant cells (arrows). H&E, 600 \times , Bar =200 μ m.

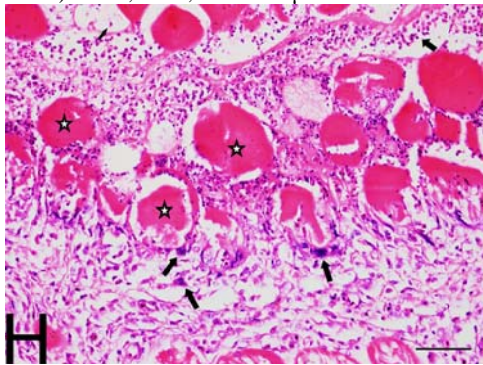


Figure-6: Histomicrograph of skeletal muscle of a broiler chicken treated with flunixin meglumine 10 mg/kg (group E). Section showing severe myodegeneration (star) with many heterophilic infiltrates (thin arrows) and scattered multinucleated giant cells (arrowhead). H&E, 400 \times Bar = 100 μ m.

Skeletal muscle: Besides urate topi as previously described there locally extensive to diffuse area of acute necrosis with large numbers of heterophils, some macrophages, a few multinucleated giant cells, and cellular and karyorrhectic debris, with severe myodegeneration with intra-sarcoplasmic floccular changes accompanied by mild to moderate phagocytosis and satellitosis (Fig. 6).

Spleen: The splenic parenchyma is scattered with many urate topi as previously described. No histopathological change was observed in organs of birds in group A (Control).

Biochemical Changes

Serum uric acid concentrations in the samples collected before treatment were 5.33 \pm 0.68 mg/dL, 5.29 \pm 0.95 mg/dL, 5.4 \pm 0.59 mg/dL, 5.42 \pm 0.53

mg/dL and 5.37 \pm 0.69 mg/dL in groups A, B, C, D and E, respectively. One bird in group C, 2 in group D and 3 in group E showed a considerable increase in these values in samples collected at subsequent intervals. These birds ultimately died within 48 to 96 hours post exposure (Fig. 7-9). Before death, serum uric acid concentrations in these birds ranged from 40 to 80 mg/dL. However, serum uric acid concentrations in the samples collected from survived birds in treatment groups were comparable to those in control birds.

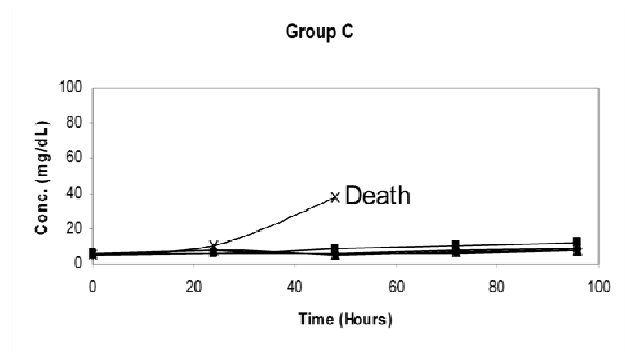


Figure-7: Serum uric acid concentrations in broiler chickens (group C, flunixin meglumine 2.5 mg/kg) at different time intervals.

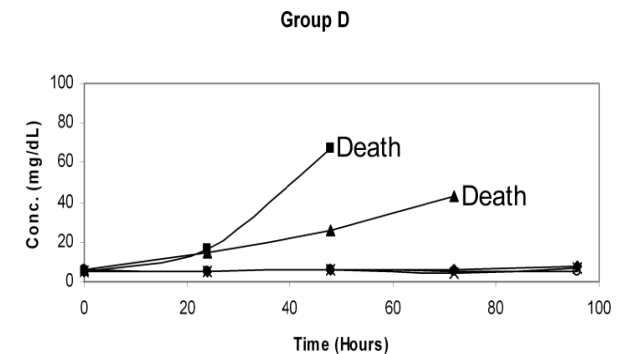


Figure-8: Serum uric acid concentrations in broiler chickens (group D, flunixin meglumine 5 mg/kg) at different time intervals.

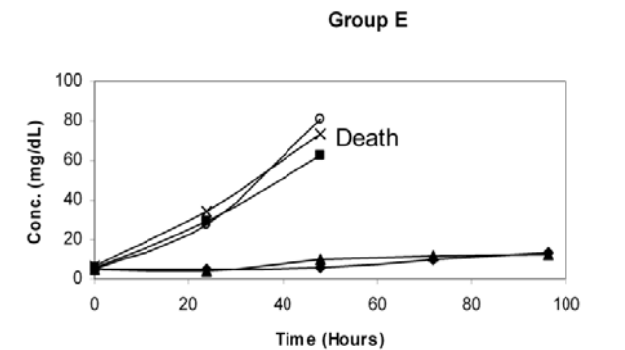


Figure-9: Serum uric acid concentrations in broiler chickens (group E, flunixin meglumine 10 mg/kg) at different time intervals.

Similarly, serum creatinine concentrations measured in samples collected pretreatment in groups A, B, C, D and E, were 0.39 ± 0.06 mg/dL, 0.39 ± 0.03 mg/dL, 0.39 ± 0.07 mg/dL, 0.38 ± 0.06 mg/dL and 0.39 ± 0.03 mg/dL, respectively. These creatinine values increased in the same birds which showed rise in serum uric acid and were died afterward (Fig.10-12). Serum creatinine concentrations remained in normal ranges in survived birds in treatment groups. No changes were observed in these values in the birds in control group.

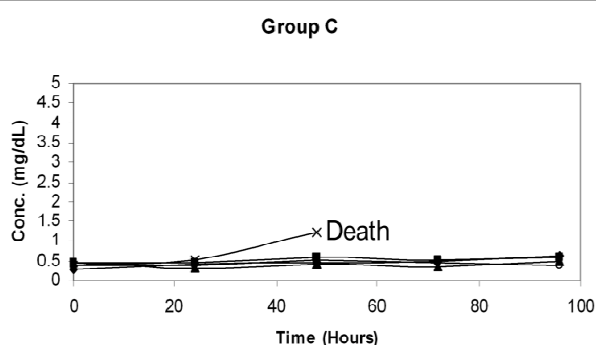


Figure-10: Serum creatinine concentrations in broiler chickens (group C, flunixin meglumine 2.5 mg/kg) at different time intervals.

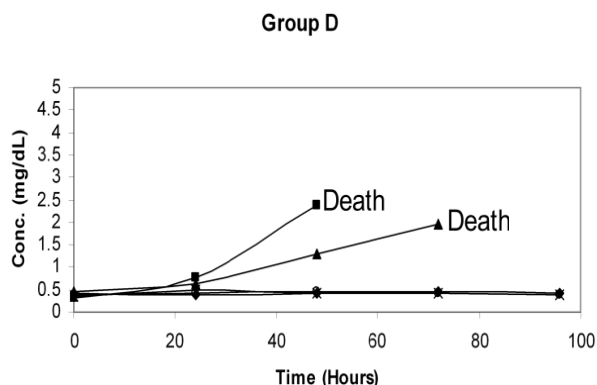


Figure-11: Serum creatinine concentrations in broiler chickens (group D, flunixin meglumine 5 mg/kg) at different time intervals.

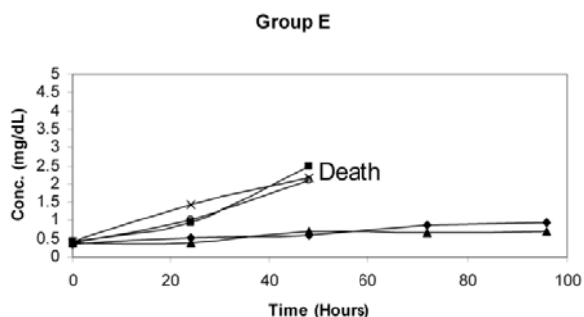


Figure-12: Serum creatinine concentrations in broiler chickens (group E, flunixin meglumine 10 mg/kg) at different time intervals.

Pretreatment serum enzyme activity measured for AST for groups A, B, C, D and E, were 126.79 ± 11.95 U/L, 121.07 ± 15.57 U/L, 126.21 ± 9.04 U/L, 126.1 ± 10.11 U/L and 123.8 ± 10.12 U/L, respectively. Serum ALT activity in the samples drawn before dosing were 23.43 ± 3.46 U/L, 22.26 ± 3.54 U/L, 21.6 ± 2.62 U/L, 21.15 ± 3.15 U/L and 23.84 U/L in groups A, B, C, D and E, while ALP activity in these groups was 536.15 ± 28.12 U/L, 533.44 ± 29.87 U/L, 542.88 ± 56.34 U/L, 536.44 ± 37.18 U/L and 540.42 ± 23.96 respectively. No significant changes were observed in serum AST, ALT and ALP in birds among treatment and control groups.

DISCUSSION

Flunixin meglumine, an NSAID, was evaluated for its toxicity in broiler chickens to determine whether this drug can be used as a safer alternative to diclofenac in animals. This study showed that this drug caused dose-dependent mortality in broiler chickens (Fig. 1). Comparable mortality rates were observed with diclofenac in broiler chickens (21). A mortality of 75-100% was recorded in vultures treated with diclofenac at the dose rate of 0.8-1.0mg/kg (6, 9). While 33-50% mortality was reported in fowls treated with diclofenac at the dose rates of 1.25 to 10mg/kg (19). This suggests that flunixin and diclofenac exhibit comparable mortality in different bird species. This study also showed that the birds that died exhibited severe clinical signs such as depression, anorexia and lethargy within 24h of treatment. These signs were similar to the clinical manifestations in vultures and fowls treated with diclofenac (6, 9, 19). Contrarily, Pereira & Werther (22) observed lack of clinical signs of toxicity in budgerigars treated with flunixin at the dose rate of 5.5mg/kg body weight, a dose at which the birds exhibited clinical signs of toxicity in the present study. The difference in observations might be attributed to the variation in species sensitivity to the drug.

A key observation of this study was that the birds that died exhibited several folds increase in serum uric acid concentration, while the birds that did not die had uric acid in normal ranges. Thus, there appears to be a causal relationship between an increase in uric acid and flunixin lethality in birds. Possible correlation between an increase in uric acid and NSAID toxicity has also been reported in different birds and mammals. In fowls, NSAIDs induced clinical signs similar to those observed in broiler chickens (19). Although not measured in the

present study, earlier studies have shown that an increase in blood uric acid might result in acidosis that has been attributed to the development of signs reported in the present study. In fowl, cattle and goat, acidosis has been linked to CNS depression (23), weakness, reluctance to suckle, deep respiration, coma, recumbency, sudden collapse and rapid death (24). We propose that the kidney damage observed in the present study and many earlier studies (25, 26, 27, 28) may interfere with uric acid and bicarbonate excretion, resulting in the development of acidosis (20, 29) and ensuing toxicity.

Postmortem examination of the birds that died exhibited severe visceral gout with excessive deposition of urates was the main postmortem lesion observed in the birds exposed to various doses of flunixin meglumine. Shultz et al. (8) found complete and highly significant association between the presence of diclofenac residues and visceral gout in dead and dying vultures collected from the wild. The findings of present study are in agreement with previous studies in which acute visceral gout with deposition of uric acid crystals on the surfaces of all visceral organs was reported in vultures died due to the diclofenac toxicity in Southeast Asia (5, 6, 30, 31). Renal and visceral gout also seen in Siberian cranes treated with flunixin meglumine (32). Necrosis of muscle tissue at the injection site was observed in this study. Similarly, severe, focally extensive pectoral muscle necrosis was reported in northern bobwhite quail injected with flunixin meglumine at dose rate of 35 mg/kg (33).

Histopathological examination was conducted on the tissue samples of kidney, liver, spleen, heart and skeletal muscles from the birds treated with flunixin meglumine. Kidneys of the birds that died showed renal tubular damage, deposition of urates tophi with macrophages and heterophil infiltration, presence of amorphous, eosinophilic material in the tubular lumen. This indicates the renal tissue damage resulted from toxic effects of the drug. These results are supported by the earlier studies which indicated the renal damage and uric acid crystal deposition in the renal tissues collected from the dead or dying vultures affected with the residues of diclofenac (6, 30, 31). Similar findings were reported in experimentally treated vultures and chickens with diclofenac (6, 9, 19, 21, 34). Flunixin meglumine is responsible for developing renal papillary necrosis in horse (35). Necrosis of renal tissue was noted in dogs receiving flunixin meglumine and methoxyflurane (26). Similar observations were also

reported in quails and budgerigars treated with flunixin meglumine (22, 33).

The lesions similar to those found in kidney tissue were also present in liver, heart, spleen and muscle samples. These observations are aligned with the various studies reported in literature (19, 21, 31, 33). The presence of lesions in liver persuaded us to study the enzymes that measure liver-function. In present study no significant change in ALT, AST and ALP activities were observed. These findings concur with the observations of Swan et al. (36) who also reported no clear pattern of change in ALT activity in response to diclofenac treatment in vultures. Thus, we propose that, despite microscopic damage in liver, liver function may not change in response to the flunixin dose used in chickens. Contrarily to the present observation, other studies have shown a rise in the levels of these enzymes in response to NSAID treatment in chickens (21) and dogs (26, 27). This could be attributed to the differences in the drug, dose of the drug, species and experimental design.

In conclusion, this study demonstrates that flunixin, similar to diclofenac, may be toxic to chicken. We propose that a rise in the blood uric acid and creatinine may be positively correlated with the toxicity. A rise in blood uric acid and creatinine in broilers treated with diclofenac at the dose rate of 5mg/kg was reported in earlier study (21). Also the flunixin-induced kidney damage may suppress uric acid excretion in urine and results in hyperuricaemia and ensuing toxicity. The increase in serum creatinine may be the result of kidney damage (26, 27, 28). This hypothesis is supported by earlier studies using diclofenac in birds and mammal (6, 9).

ACKNOWLEDGEMENT

This study was supported by the Higher Education Commission of Pakistan.

REFERENCES

1. Prakash, V.: Status of vultures in Keoladeo National Park, Bharatpur, Rajasthan, with special reference to population crash in *Gyps* species. *J. Bomb. Nat. Hist. Soc.*, 1999; 96:365–378.
2. Prakash, V., Pain, D. J., Cunningham, A. A., Donald, P. F., Prakash, N.:
3. Catastrophic collapse of Indian white-backed *Gyps bengalensis* and long-billed
4. *Gyps indicus* vulture populations. *Bio. Con.*, 2003; 109: 381–390.
5. Gilbert, M., Virani, M. Z., Watson, R. T., Oaks, J.L., Benson, P.C., Khan, A. A., Ahmed, S., Chaudhry, J., Arshad, M., Mehmood, S., Shah, Q. A.: Breeding and mortality of Oriental white-backed vulture *Gyps bengalensis* in Punjab Province, Pakistan. *Bird Conserv Int.*, 2002; 12: 311–26.

6. IUCN.: IUCN Red List of Threatened Species., 2006 <http://www.iucnredlist.org/>
7. Pain D. J., Cunningham, A. A., Donald, P. F., Duckworth, J. W., Houston, D. C., Katzner, T., Parry-Jones, J., Poole, C., Prakash, V., Round, P., Timmins, R.: Causes and Effects of Temporospatial Declines of *Gyps* Vultures in Asia. *Conserv Biol.*, 2003; 17 (3): 661–671.
8. Oaks, J. L., Gilbert, M., Virani, M. Z., Watson, R. T., Meteyer, C. U., Rideout, B., Shivaprasad, H. L., Ahmed, S., Chaudhry, M. J. I., Arshad, M., Mahmood, S., Ali, A., Khan, A. A.: Diclofenac residues as the cause of vulture population declines in Pakistan. *Nature.*, 2004; 427, 630–633.
9. Risebrough, R.: Conservation biology: fatal medicine for vultures. *Nature.*, 2004; 427(6975):596-8.
10. Shultz, S., Baral, H. S., Charman, S., Cunningham, A.A., Das, D., Ghalsasi, G. R.: Diclofenac poisoning is widespread in declining vulture populations across the Indian subcontinent. *Proc R SocLond B.*, 2004; 271: S458–60.
11. Swan, G.E., Cuthbert, R., Quevedo, M., Green, R.E., Pain, D.J., Bartels, P., Cunningham, A.A., Duncan, N., Meharg, A., Oaks, J.L., Parry-Jones, J., Schultz, S., Taggart, M.A., Verdoorn, G.H., Wolter, K.: Toxicity of diclofenac in *Gyps* vultures., *Biol. Lett.*, 2006a; 2: 1–4.
12. Chay, S., Woods, W. E., Nugent, T.: The pharmacology of nonsteroidal anti-inflammatory drugs in the horse: flunixin meglumine (Banamine). *Equine Pract.*, 1982; 4:16–23.
13. Erkert, R. S., MacAllister, C. G., Payton, M. E., Clarke, C. R.: Use of force plate analysis to compare the analgesic effects of intravenous administration of phenylbutazone and flunixin meglumine in horses with navicular syndrome. *Am J Vet Res.*, 2005; 66 (2): 284-288.
14. Kallings, P.: Nonsteroidal anti-inflammatory drugs. *Vet Clin North Am Equine Pract.*, 1993; 9: 523–562.
15. Baskett, A., Barton, M. H., Norton, N., Anders, B. and Moore, J. N.: Effect of pentoxifylline, flunixin meglumine, and their combination on a model of endotoxemia in horses. *Am J Vet Res.*, 1997; 58: 1291–1299.
16. Hirsch, A. C., Philipp, H., Kleemann, R.: Investigation on the efficacy of meloxicam in sows with mastitis–metritis–agalactiasyndrome. *J. Vet. Pharmacol. Therap.*, 2003; 26: 355–360.
17. Drillich, M., Voigt, D., Forderung, D., and Heuwieser, W.:Treatment of acute puerperal metritis with flunixin meglumine in addition to antibiotic treatment. *J. Dairy Sci.*, 2007; 90: 3758–3763.
18. Lockwood, P. W., Johnson, J. C., Katz, T. L.: Clinical efficacy of flunixin, carprofen and ketoprofen as adjuncts to the antibacterial treatment of bovine respiratory disease. *Vet Rec.*, 2003; 152: 392-394.
19. Baert, K., De Backer, P.: Disposition of sodium salicylate, flunixin and meloxicam after intravenous administration in broiler chickens. *J. Vet. Pharmacol. Ther.*, 2002; 25(6): 449–453.
20. Baert, K., De Backer, P.: Comparative pharmacokinetics of three non-steroidal anti-inflammatory drugs in five bird species. *Comp. Biochem. Physiol. C ToxicolPharmacol.*, 2003; 134 (1): 25–33.
21. Naidoo, V., Duncan, N., Bekker, L., Swan, G.: Validating the domestic fowl as a model to investigate the pathophysiology of diclofenac in *Gyps* vultures. *Environ. Toxicol. Pharmacol.*, 2007; 3: 260-266.
22. Speer, B. L.: Diseases of the urogenital system. In *Avian Medicine and Surgery*. (Eds) Altman, R. B., Clubb, S. L., Dorrestein, G. M., Quesenberry, K. Philadelphia, W. B. Saunders., 1997; 625-644.
23. Reddy, P. N. C., Anjaneyula, Y., Sivasankari, B., Rao, A. K.: Comparative toxicity studies in birds using nimesulide and diclofenac sodium. *Environ. Toxicol. Pharmacol.*, 2006; 22: 142–147.
24. Pereira, M. E., Werther, K.: Evaluation of the renal effects of flunixin meglumine, ketoprofen and meloxicam in budgerigars (*Melopsittacusundulatus*). *Vet Rec.*, 2007; 160(24): 844-6.
25. Blood, D.C., Radostits, O.M.: *Veterinary Medicine. A textbook of Diseases of Cattle, Sheep, Pigs, Goats and Horses.* BailliereTindall, London., 1989; 64-66.
26. Radostits, O. M., Gay, C. C., Hinchcliff, K. W., Constable, P. D.: Disturbances of free water, electrolytes and acid-base balance. In *Veterinary Medicine*. 10th Ed. Saunders, Elsevier., 2007; 82-86.
27. Elwood, C., Boswood, A., Simpson, K., Carmichael, S.: Renal failure after flunixin meglumine administration. *Vet Rec.*, 1992; 130(26): 582-583.
28. Mathews, K. A., Doherty, T., Dyson, D. H., Wilcock, B., Valliant, A.: Nephrotoxicity in dogs associated with methoxyflurane anesthesia and flunixin meglumine analgesia. *Can Vet J.*, 1990; 31: 766-771.
29. Mathews, K. A., Paley, D. M., Foster, R. F., Valliant, A., Young, S. S.: A comparison of ketorolac with flunixin, butorphanol, and oxymorphone in controlling postoperative pain in dogs. *Can Vet J.*, 1996; 37: 557-567.
30. Murray, M. D. &Brater, D. C.: Renal toxicity of the nonsteroidal anti-inflammatory drugs. *Annu. Rev. Pharmacol. Toxicol.*, 1993; 33: 435–465.
31. Seifter, J. L.: Acid–base disorders. In: Arend, W. P., Drazen, J. H., Ill, G. N., Riggs, R. C., Owell, D. W., Cheld, W. M. (Eds.), *Cecil Textbook of Medicine*. W.B. Saunders Company, Philadelphia., 2004; 688–695.
32. Cunningham, A. A., Prakash, V., Pain, D., Ghalsasi, G. R., Wells, G. A. H., Kolte, G. N., Nighor, P., Goudar, M. S., Kshirsagar, S., and Rahmani, A.: Indian vultures: Victims of an infectious disease epidemic? *Animal Conservation.*, 2003; 6: 189–197.
33. Mishra, S. K., Prasad, G., Minakshi, Malik, Y., Mahajan, N. K. and Prakash, V.: Vulture mortality: pathological and microbiological investigations. *Indian J Anim Sci.*, 2002; 72: 283-286.
34. Clyde, V. L., Murphy, J.: Avian analgesia. In: Fowler, M. E., Miller, R. E. (Eds.), *Avian Medicine. Zoo & Wild Animal Medicine: Current Theory*, vol. 4. W.B. Saunders, Philadelphia., 1999; 309–314.
35. Klein, P. N., Charmatz, K. and Langenberg, J.: The effect of flunixin meglumine (Banamine) on the renal function in northern bobwhite (*Colinusvirginianus*): An avian model. *Proceedings of the American Association of Zoo Veterinarians and Association of Reptilian and Amphibian Veterinarians Conference*, Pittsburgh, Pennsylvania, R. E. Junge (Ed.). American Association of Zoo Veterinarians, Philadelphia, Pennsylvania., 1994; 128–131.
36. Meteyer, C. U., Rideout, B. A., Gilbert, M., Shivaprasad, H. L. & Oaks, J. L.: Pathology and proposed pathophysiology of diclofenac poisoning in free-flying and experimentally-exposed oriental white-backed vultures (*Gyps bengalensis*). *J. Wildl. Dis.*, 2005; 41: 4.
37. Faulkner, L. W., Erb, H. N. and King, J. M.: Renal Papillary Necrosis in Equines. *Bull Environ. Contam. Toxicol.*, 1984; 33: 379-381.
38. Swan, G., Naidoo, V., Cuthbert, R., Green, R.E., Pain, D.J., Swarup, D., Prakash, V., Taggart, M., Bekker, L., Das, D., Diekmann, J., Diekmann, M., Killian, E., Meharg, A., Patra, R.C., Saini, M., Wolter, K., Removing the threat of diclofenac to critically endangered Asian vultures. *PLoS Biol.*, 2006b; 4: 395–402.